

**PATIENT**

Tucker Sims

SPECIES

Canine

BREED

Bichon Frise

SEX

Male Intact

AGE

7.9.13

WEIGHT

13.3lbs

PRESENTING CLINICAL SIGNS

History: Seen 1 week ago for dyspnea at ER. Grade 5/6 murmur. Doing better post ER visit.

-Pertinent abnormal PE/Chem/CBC/UA Results: WNL from ER. Rads- Cardiomegaly at ER.

-Current medications: Lasix 10mg BID, Vetmedin 2.5mg BID.

-Sedation used: Torbugesic.

-Pertinent previous ultrasound results: No previous.

-STAT: Not requested.

-Imaging performed by: Stephanie Warga RDCS, RVT.

RADIOGRAPHIC FINDINGS *NOTE: Images submitted for supplemental information only.

Severe cardiomegaly with evidence of CHF.

ECHOCARDIOGRAM FINDINGS

2D, m-mode, color flow and doppler imaging is available. Diffuse thickening of mitral valve leaflets with prolapse into the left atrial lumen. Severe eccentric mitral regurgitation with severe left atrial dilation. Normal MR velocity. Mild LV dilation with hyperdynamic myocardial function. The tricuspid valve appears normal, with mild TR. Mildly elevated velocity. Normal right atrial and ventricular diameter and morphology. The pulmonic and aortic valves are normal in morphology and mobility. Normal aortic and pulmonic outflow velocities with laminar flow. No AI/PI. No pericardial or pleural effusion noted. No obvious cardiac masses.

CARDIAC CHART**INTERPRETED BY**Maggie Machen Lamy,
DVM, DACVIM
(Cardiology)**HOSPITAL NAME**Northwind Animal
Hospital**REFERRING VET**

Dr. Cross

INVOICE

27723

DATE

11.30.22

CANINE CARDIAC PARAMETERS	MR VMAX (m/s)	TR VMAX (m/s)	LA/AO (Boon method)	LA/AO (Heart Base; Swe)	FS (%)	EF (%)	EPSS (cm)
NORMAL PARAMETER	4.5-5.5	<2.7	1.3	<1.6	28-40	40-100	<0.6
PATIENT	6.0	3.0	NM	2.0	48	80	NM
CANINE CARDIAC PARAMETERS	HR (BPM)	AV VMAX (m/s)	PV MAX (m/s)	BODY WEIGHT (kg)	LA 2D short axis Base view (cm)	LVIDd Avg; 2D and m-mode short axis (cm)	LVIDs Avg; 2D and m-mode short axis (cm)
NORMAL PARAMETER	50-100	0.7-1.7	0.7-1.6	BELOW	BELOW	BELOW	BELOW
PATIENT	130	1.4	0.9	6.0	3.1	4.0	2.1
*Normal chamber parameters expressed as a mean value (SD)				3	1.27 (5.3)	2.46 (2.46)	1.36 (5.5)
BODY WEIGHT DEPENDENT PARAMETERS				5	1.40 (4.5)	2.74 (5.2)	1.60 (4.7)
*Note: All measurements based upon multi-modal images and methods. An average value is reported.				10	1.50 (3.8)	3.27 (3.5)	2.06 (3.1)
				15	1.83 (2.0)	3.71 (2.4)	2.43 (2.1)
				20	2.02 (1.9)	4.14 (2.2)	2.80 (2.0)
				25	2.18 (2.4)	4.48 (2.9)	3.10 (2.5)
				30	2.33 (3.3)	4.83 (3.9)	3.39 (3.4)
				35	2.48 (4.3)	5.17 (5.0)	3.69 (4.5)
				40	2.62 (5.2)	5.48 (6.1)	3.96 (5.4)
				50	2.88 (7.1)	6.07 (8.3)	4.46 (7.4)

Adapted from June Boon, Veterinary Echocardiography, 1998
 Rishniw M and Hollis NE, J Vet Intern Med 2000; 14:429-435
 Hansson et al, Vet Rad and Ultrasound 2002
 Bonagura et al. Echocardiography: principles of interpretation, Vet Clin North Am 15:1177, 1995

INTERPRETATION OF THE FINDINGS & FURTHER RECOMMENDATIONS

The cause of the murmur is chronic degenerative valve disease causing severe mitral and mild tricuspid regurgitation. Severe left atrial enlargement indicates the risk for spontaneous congestive heart failure is elevated. Early pulmonary hypertension is noted, which is likely secondary to chronic LA pressure elevation. No additional issues are identified.

In light of the clinical signs, chest radiograph findings and severity of disease on echocardiogram, the diagnosis is congestive heart failure and continued medications are warranted lifelong as below. Monitoring of sleeping respiratory rates will be paramount to screen for congestive heart failure at home. Cough suppression to improve QOL can also be considered (hydrocodone, 0.2-0.4mg/kg up to q4-6h PRN) for any residual mechanical cough in the face of normal sleeping respiratory rates. The average survival time of canine patients with active pulmonary edema is 8-9 months on medications, however they generally are able to maintain a good quality of life for that period. Patient will always be at risk for recurrent CHF, development of arrhythmias/LA tear, syncope and/or sudden death in the future.

Omega fatty acid supplementation and mild salt restriction may also be of some long-term benefit. Monitor for acute progression of the cough, labored breathing, exercise intolerance or collapse episodes in the future.

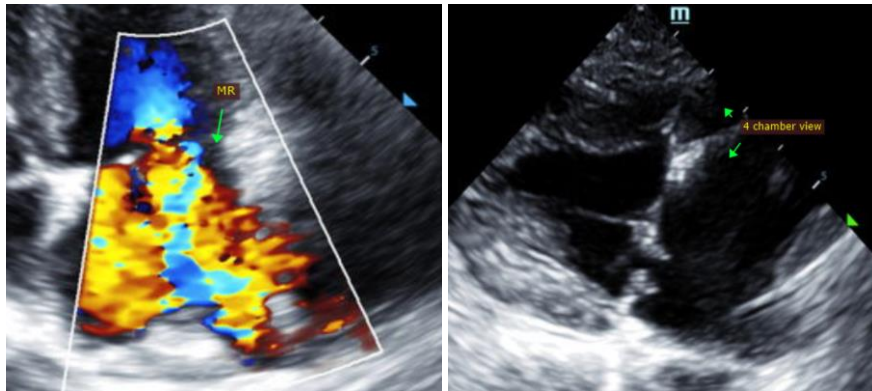
PLAN

Administer Pimobendan 0.3mg/kg PO q12h. Administer Furosemide 1-2mg/kg PO q12h. Institute spironolactone 1-2mg/kg PO q12h.

Monitor SRRs at home. Monitor renal values and BP in 10-14 days, then every 3-4 months while on diuretics. If doing well and BP >130mmHg, institute ACEI 0.5mg/kg PO q12h. Consider hydrocodone if needed for QOL.

Recommend conservative monitoring with a recheck echocardiogram in 6 months, sooner if any development of associated clinical signs occurs in the interim.

IMAGES



The information and recommendations provided are based on the images presented by the referring veterinarian. No evaluation can be communicated regarding pathology that was not visible in the image/video clips provided.

Thank you for this referral. This report was generated using transcription software, and minor dictation errors may be present. If the clinical or image interpretation does not parallel your findings or if I can be of any further assistance, please contact me.

Maggie Machen Lamy, DVM
Diplomate of the American College of Veterinary Internal Medicine (Cardiology)
info@sonopath.com